Barcelona – September 2015

Displacement of calcium hydroxide paste in the inferior alveolar canal : transient and permanent paresthesia.

Siquet J.-P.*, De Moor R.°, Meire M.°

* Cabinet du Lion Endodontie Exclusive, Braine-l'Alleud, Belgium. ° Dept. Restorative Dentistry & Endodontology, Ghent University, Ghent, Belgium.

Aim : to discuss the consequences of accidental extrusion of calcium hydroxide paste in the mandibular canal.

Introduction : Denio et al. revealed that the apices of the second lower molars are on average located 3.7 mm from the upper border of the mandibular canal and that the mesial root apices of the first molars are further from the alveolar canal by about 6.9 mm (1). Calcium hydroxide pastes are intracanal antimicrobial agents of choice in endodontic therapy (2). Care has to be taken, as calcium hydroxide paste is able to induce intense inflammatory responses leading to necrotic and degenerative changes in animal models (3). The normal therapeutic sequence for injuries to inferior alveolar nerve (IAN) is the control of pain and inflammation and, whenever possible, the surgical elimination of the cause (4).

Case report : A 29-year-old woman without contributing medical condition was referred to complete endodontic treatment of tooth 46. Six weeks earlier, a pulpectomy had been performed and calcium hydroxide paste (Ultracal XS, Ultradent Products Inc. U.S.A) had been placed in the root canals with a syringe and a plastic needle. At the same time, extrusion of this paste into the inferior alveolar canal had occurred from the level of tooth 46 up to the mandibular foramen (fig1).

The patient had first complained of stabbing pain when the lower lip was mobilized and numbness of the left chin. Immediately after the event, she was given 24 mg of methylprednisolone per day for one week. She, then, started lowering the doses and stopped the medication at the end of the second week. The stabbing pain had disappeared but not the numbness.

The patient also reported having had the same accident when tooth 36 underwent pulpectomy and calcium hydroxide paste (type unknown) placement in 2002. The amount of extruded calcium hydroxide was less important than on the right side (fig 1). It was then decided to extract the tooth the same day. The numbness gradually disappeared without intervention over a period of 4 months.

Gambarini et al. considered cone-beam computed tomography (CBCT) an effective radiographic technique when endodontic-related IAN paresthesia is suspected (5). In the present case, CBCT clearly showed that the apices of tooth 46 were in contact with the inferior alveolar canal (figs 3 & 4). It also suggested that the extrusion occurred through the distal canal (fig 5). Information on possible apical damage during preparation was not provided. Clinical examination with thermal and mechanical tests confirmed paresthesia of the area of innervation of the inferior alveolar nerve (fig 4).

The endodontic treatment of tooth 36 was performed in one appointment (figs 6,7 & 8). After anesthesia and isolation of the tooth with a rubberdam, the access cavity was refined. Working length was then measured with an electronic apex locator (Root ZX, Morita, Japan) and confirmed with a periapical radiograph. The distal canal was instrumented using K-files up to size 55 in a step-back technique. The mesial canals were prepared with nickel-titanium rotary files up to size 40 (Revo-S, Micro-Mega, Besançon, France). The root canals were irrigated with 2,5 % sodium hypochlorite and 17% EDTA. The tooth was filled with gutta percha and AH+ (Dentpsly De Trey, Konstanz, Germany) using the lateral condensation technique.

Paresthesia was monitored for up to 32 months from the initial consultation and did not show any improvement. The displaced calcium hydroxide paste did not show signs of resorption (fig 9).

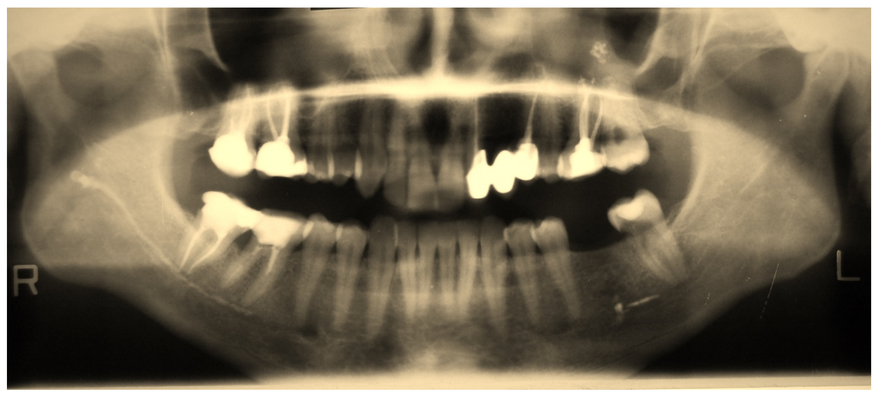

Figure 1

Figure 2

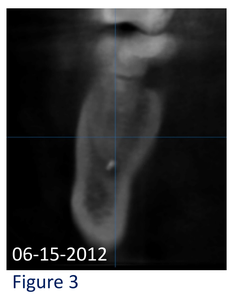

Figure 3

Figure 4

Figure 5

Fig1 : OPG taken by the general dentist
Fig2 : CBCT cross sectional distal root
Fig3 : CBCT cross sectional mesial root
Fig4 : Area of paresthesia
Fig5 : CBCT panorama
Fig6 : Pre-operative X-ray
Fig7 : Root canal length X-ray
Fig8 : Endodontic treatment final X-ray
Fig9 : OPG 32 months recall

Figure 6

Figure 7

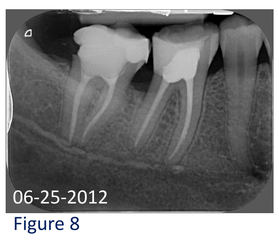

Figure 8

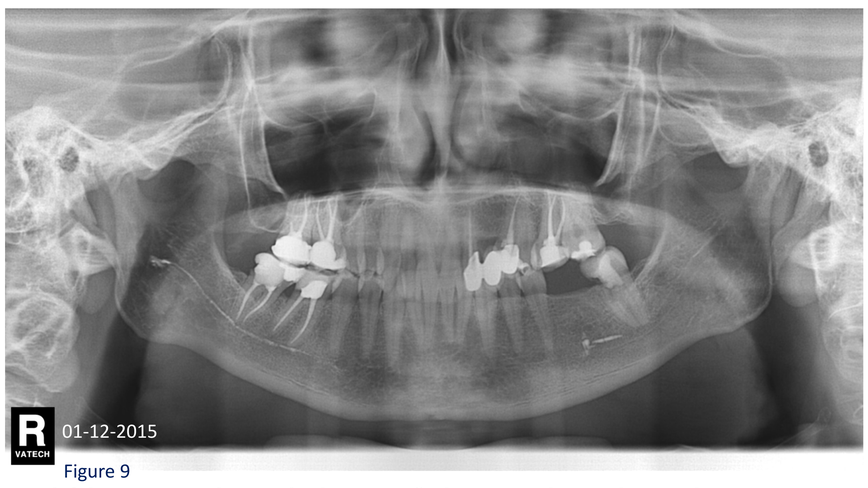

Figure 9

Conclusions and key learning points :

- Delivering calcium hydroxide paste with a syringe and needle should be done carefully : the needle should be introduced short of the working length and fit loosely in the canal to avoid forcing the paste outside of the root canal.
- Extrusion of calcium hydroxide paste in the inferior alveolar canal can cause paresthesia that may be permanent. The amount of extruded calcium hydroxide paste probably plays a role.
- Calcium hydroxide paste does not show signs of resorption when displaced in the inferior alveolar canal.
- The prescription of corticosteroids was of very little help in the management of the paresthesia.

References :

1. Denio D, Torabinejad M, Bakland LK (1992) Anatomical relationship of the mandibular canal to its surrounding structures in mature mandibles. *Journal of Endodontics* **18**, 161-165.
2. Mohammadi Z, Dummer PM (2011) Properties and applications of calcium hydroxide in endodontics and dental traumatology. *International Endodontic Journal* **44**, 697-730.
3. Nelson Filho P, Silva LA, Leonardo MR, Utrilla LS, Figueiredo F (1999) Connective tissue responses to calcium hydroxide-based root canal medicaments. *International Endodontic Journal* **32**, 303–311.
4. Pogrel MA (2007) Damage to the inferior alveolar nerve as the result of root canal therapy. *The Journal of the American Dental Association* **138**, 65–9.
5. Gambarini G, Plotino G, Grande NM, Testarelli L, Prencipe M, Messineo D, Fratini L, D'Ambrosio F (2011) Differential diagnosis of endodontic-related inferior alveolar nerve paresthesia with cone beam computed tomography : a case report. *International Endodontic Journal* **44**, 176-181.